



ORIGINAL ARTICLE

Medicine Science 2021;10(4):1402-5

Surgical management and its outcomes in distal anterior cerebral artery aneurysms

 Mehmet Secer¹,  Aykut Gokbel²

¹Alaaddin Keykubat University, School of Medicine, Department of Neurosurgery, Antalya, Turkey

²Derince Training and Research Hospital, Neurosurgery Clinic, Kocaeli, Turkey

Received 20 August 2021; Accepted 24 September 2021

Available online 24.11.2021 with doi: 10.5455/medscience.2021.08.264

Copyright@Author(s) - Available online at www.medicinescience.org

Content of this journal is licensed under a Creative Commons Attribution-NonCommercial 4.0 International License.



Abstract

The present study aimed to discuss the clinical and surgical outcomes of patients who underwent surgery for distal anterior cerebral artery aneurysm (DACA). Surgery for DACA aneurysms differs from other intracranial aneurysms and has its own challenges. The study included nine patients with DACA aneurysm who consented to undergo microsurgical treatment. The study data were collected by retrospectively reviewing the clinical, radiological, and intraoperative findings, as well as postoperative morbidity and mortality outcomes. A total of ten DACA aneurysms were detected in nine cases. Microsurgical treatment was performed for nine aneurysms. The multiple aneurysm rate was 33.3%. While no morbidity was observed in patients with DACA aneurysm in this study, the mortality rate was 11.1%. The surgery for DACA aneurysms is complicated due to challenges, such as difficulty in achieving proximal control, narrow working space, and difficulty in dissection due to tight adhesion of the aneurysm to the surrounding tissues. For these reasons, surgical outcomes may be adversely affected. Surgical clipping can be performed using appropriate surgical approach and microsurgical techniques.

Keywords: Distal anterior cerebral artery, aneurysm, microsurgery

Introduction

The term distal anterior cerebral artery (DACA) is used to describe arterial segment distal to the Anterior communicating Artery (ACoA) [1]. DACA aneurysms constitute a special group of aneurysms located anterior to the circle of Willis [2]. The incidence of DACA aneurysms is 1.5% to 9% among all intracranial aneurysms [1-5]. Surgery of DACA aneurysms differs from that of other aneurysms due to technical reasons, such as difficulty in achieving proximal control, narrow working space, difficulty in dissection due to tight adhesions between the aneurysm and the surrounding tissues. These factors can negatively affect the surgical outcomes [1,2].

The present study aims to discuss the clinical and surgical outcomes of nine patients who underwent surgery for ten DACA aneurysms.

Materials and Methods

We retrospectively evaluated nine patients who underwent surgery for ruptured DACA aneurysm that caused subarachnoid hemorrhage (SAH) and/or intracerebral-intraventricular hematoma. The study was approved by the Ethical Committee, report no: 2021-73, and was carried out in accordance with The Code of Ethics of the World Medical Association (Declaration of Helsinki). Among the nine patients, six were female and three were male. The mean age of the patients was 46.8 (31–54) years. Computed tomography (CT) of the head revealed SAH in basal cisterns in one patient, intracerebral hematoma localized in the hematoma site in six patients, and intracerebral and intraventricular hemorrhage in two patients. Ten DACA aneurysms were detected in nine patients with the help of CT angiography and/or digital subtraction angiography (DSA). The aneurysm observed on CT angiography and DSA was localized at the A2 segment in one patient and at the A3 segment in eight patients, one of whom had bilateral DACA aneurysm. One patient had a secondary ACoA aneurysm accompanying a hemorrhagic DACA aneurysm, and another patient had a total of three aneurysms localized at the A3 segment, ACoA, and paraclinoid internal carotid artery (Figure 1). The multiple aneurysm rate was 33.3%. Preoperative Hunt-Hess grade, radiological localization and size of the aneurysm, presence of multiple aneurysms, type

*Corresponding Author: Mehmet Secer, Alaaddin Keykubat University, School of Medicine, Department of Neurosurgery, Antalya, Turkey
E-mail: memetsecer@yahoo.com

Table 1. Clinical, radiographic, and demographic distribution of the cases

Patient	Age/gender	Hunt&Hess grade	ICH/IVH	Size	Localization	Multiple Aneurysm	Surgical Approach / Lumbar or ventricular Drainage	Surgery	GOS
1	54 / F	2	+/-	9 mm	A3	-	Interhemispheric / LD	clipping	5
2	50 / F	2	-/-	4 mm	A2	-	Pterional/LD	wrap-ping	5
3	48 / F	2	+/+	7 mm	A3	-	Interhemispheric / absent	clipping	5
4	48/M	3	+/-	8 mm	A3	-	Interhemispheric / LD	clipping	5
5	31/M	1	+/-	2.6 mm	A3	Ant. Com	Pterional + Interhemispheric / LD	clipping	5
6	48 / F	4	+/+	5 mm	A3	-	Interhemispheric / LD	clipping	1
7	46 / F	2	+/-	6.9 / 9.4 mm	A3	Bilateral A3	Interhemispheric / absent	clipping	5
8	45 / F	2	+/-	7 mm	A3	Ant. Com artery, Paraclinoid Carotid artery	Interhemispheric / LD	clipping	5
9	52 / F	4	+/+	6.6 mm	A3	-	Interhemispheric/VD	clipping	5

ICH: Intracerebral hematoma, IVH: Intraventricular Hematoma, LD: Lumbar drainage, VD: Ventricular drainage GOS: Glasgow Outcome Scale

of accompanying hemorrhage, and Glasgow outcome scale (GOS) scores of the patients were evaluated (Table 1).

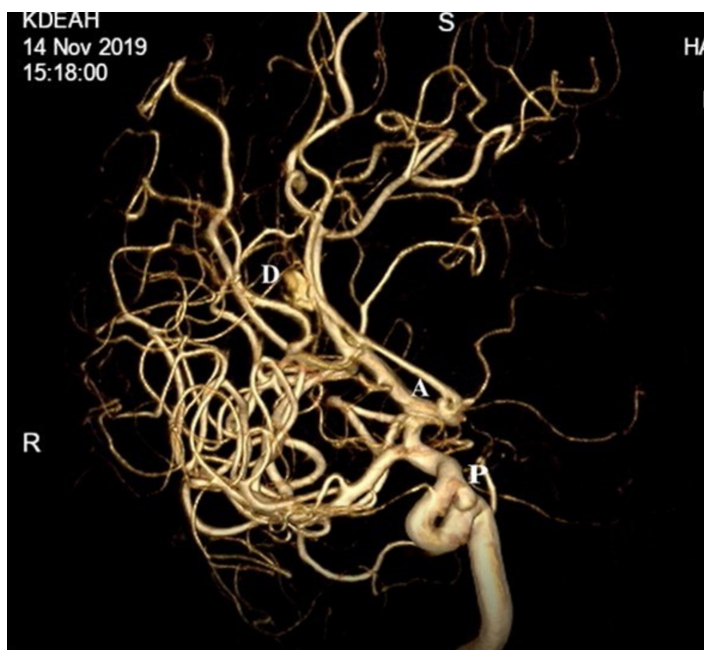

Figure 1. DSA image of a patient with multiple aneurysms accompanying bleeding DACA aneurysm. D: DACA A3 aneurysm, A: Anterior communicating artery aneurysm, P: paraclinoid carotid artery aneurysm

Surgical treatment

A lumbar drain was inserted before proceeding with surgery in five patients with interhemispheric SAH. Lumbar drainage was not performed in patients with a large hematoma and ventricular hemorrhage accompanying the aneurysm. External ventricular drainage was applied in a case of massive intraventricular hemorrhage accompanied SAH. A patient with an aneurysm at the A3 segment accompanying (ACoA) aneurysm underwent both interhemispheric and pterional craniotomy. Pterional craniotomy was performed in one patient with A2 aneurysm. The operating table was flexed with the head fixed with the Mayfield frame and

hyperextended in neutral position above the cardiac level for the interhemispheric approach. After performing the horseshoe skin incision crossing the midline, the dura was incised in a curvilinear fashion and reflected toward the sagittal sinus following right frontal craniotomy near the midline. Attempts were made to preserve the veins draining into the sagittal sinus. The surgical field was further deepened by interhemispheric dissection to evacuate hematoma. There was premature rupture in the dissection phase in two cases. A permanent clip was placed after the bleeding was controlled with the placement of a proximal clip in one patient with premature rupture and placement of a trial clip in the other. After clipping, blood flow in the parent arteries was controlled with a micro Doppler probe. Papaverine-soaked sponges were placed in the vascular bed.

Surgical outcomes

Wrapping was performed in a patient with A2 aneurysm after SAH that was not suitable for clipping. A total of nine A3 aneurysms, including those in a patient with bilateral DACA aneurysm, were clipped. In addition to interhemispheric approach in one patient with a secondary ACoA aneurysm accompanying A3 aneurysm, the aneurysm was clipped with pterional craniotomy. The aneurysms located at the A3 segment and ACoA were clipped in the same session using the interhemispheric approach in a patient who had multiple aneurysms at the A3 segment, ACoA, and paraclinoid internal carotid artery aneurysm. The same patient preferred endovascular therapy for paraclinoid internal carotid artery aneurysm. Postoperative morbidity was not observed, and one patient with a Hunt & Hess grade five died due to vasospasm on day 7 (11.1%).

Discussion

Surgery of DACA aneurysms differs from that of other intracranial aneurysms and has its own challenges [2,3,5]. These challenges arise from morphological factors, such as deep interhemispheric localization, absence of anatomical landmarks, aneurysm being embedded in the surrounding brain tissue, small aneurysm size,

broad base, and presence of arterial branches close to the aneurysm base [3,6]. Therefore, some studies have suggested the use of neuro-navigation to localize DACA aneurysm and preoperative lumbar drainage for brain relaxation [2,7]. Neuro-navigation was not used in this study. Preoperative lumbar drainage was performed for brain relaxation in five patients without a large intracerebral hematoma. External ventricular drainage was applied in a case of massive intraventricular hemorrhage. Due to the relaxation provided by lumbar drainage, both A3 and ACoA aneurysms could be clipped using the interhemispheric approach in one patient. For craniotomy localization, planning was made according to the relationship between coronal suture and the aneurysm as assessed by CT angiography and DSA. Because the aneurysm projection is toward the surgeon, the aneurysm may prematurely rupture during retraction of the falx or frontal lobe before exposing the neck of the aneurysm[3,6]. Interhemispheric craniotomy was performed for eight A3 aneurysms in seven patients, and pterional craniotomy was performed for A2 aneurysm in one patient. Orz reported that the rate of premature rupture was 35% in their study [5]. Premature rupture occurred during dissection in two patients in the present study (25%). A permanent clip was placed after the bleeding was controlled with the placement of a proximal clip in one patient with premature rupture and placement of a trial clip in the other.

DACA aneurysms are usually small in size. Ohno et al. reported that 67% of ruptured DACA aneurysms were smaller than 6 mm [8], while Şekerci et al. reported that 60% were between 3–6 mm in size[1]. In our series, the smallest aneurysm was 2.4 mm and the largest aneurysm was 9.4 mm in size, while the rate of aneurysms smaller than 6 mm was 30%. Rare incidence of DACA aneurysms may be due to rupture before reaching large dimensions. Due to the absence of an enduring arachnoid membrane in pericallosal cysterns, DACA aneurysms may cause bleeding regardless of their size [9]. For these reasons, we support the idea of performing early surgery in non-ruptured DACA aneurysms [1,5], even if we have detected a patient incidentally.

DACA aneurysms have high tendency of being multiple. The incidence of multiple DACA aneurysms was found to be 46.4% by Hernesniemi et al. [10], 42.9% by Ohno et al. [8], 38.5% by Yaşargil et al. [3], and 21% by Orz et al. [5]. In our study, multiple aneurysms were detected in three patients: two had aneurysms accompanying ACoA aneurysm, one of whom also had a third aneurysm in the paraclinoid internal carotid artery, and one had bilateral DACA aneurysms (Figure 2). Therefore, patients with DACA aneurysm should be evaluated in detail considering that there may be secondary and tertiary aneurysms.

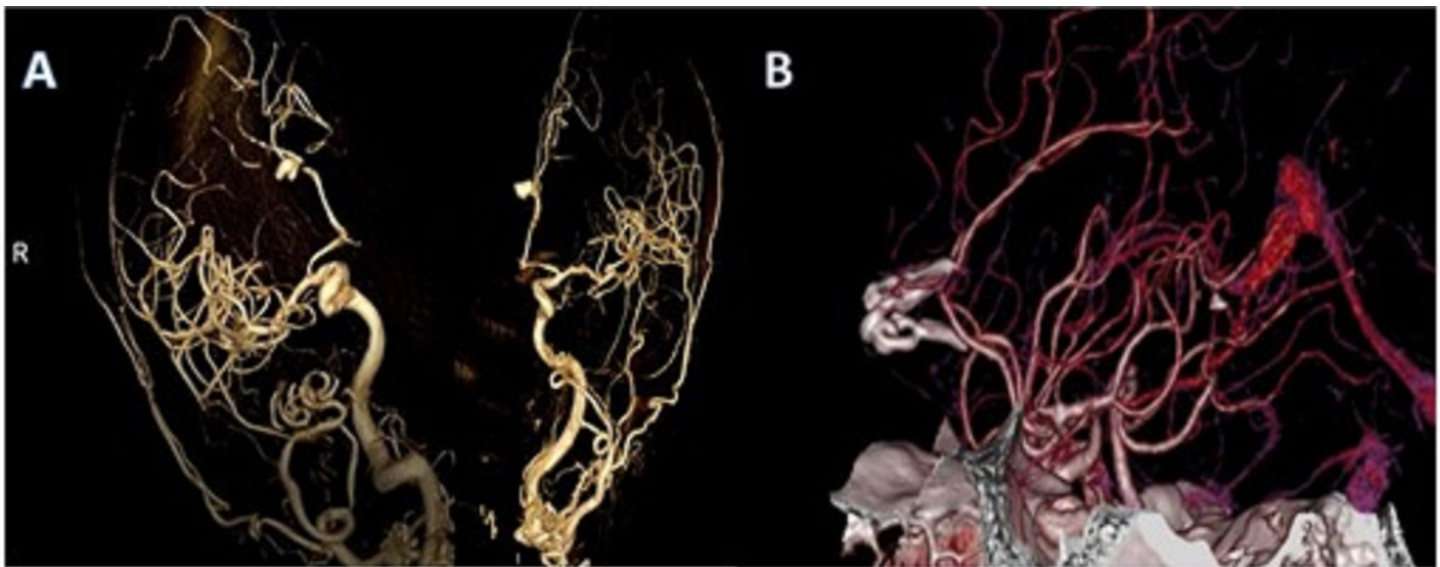


Figure 2. Bilateral DACA aneurysm DSA image, B; Postoperative CT angiography image after clipping

Various surgical approaches have been described for the repair of DACA aneurysms. Fukushima et al. suggested the unilateral interhemispheric keyhole approach for aneurysms located in the anterior midline [11]. Gyrus rectus resection with standard pterional craniotomy can be used for fronto-basal or proximal aneurysms [10,12]. Traynelis and Dunker recommended performing a small anterior callosotomy for achieving proximal control of the aneurysm [13]. In our study, unilateral interhemispheric approach was used in A3 aneurysms, and pterional craniotomy was used in proximal A2 aneurysms. Gyrus rectus excision or callosotomy was not added to these approaches.

In conclusion, it must be kept in mind that DASA aneurysms have a high tendency of being multiple. Lumbar and ventricular drainage

in appropriate cases facilitates dissection by providing brain relaxation. Pterional approach should be preferred in proximal A2 aneurysms and interhemispheric approach should be preferred in A3 aneurysms.

Conflict of interests

The authors declare that they have no competing interests.

Financial Disclosure

All authors declare no financial support.

Ethical approval

The study was approved by the Ethical Committee, report no: 2021-73, and was carried out in accordance with The Code of Ethics of the World Medical Association (Declaration of Helsinki).

References

1. Sekerci Z, Sanli M, Ergun R, et al. Aneurysms of the distal anterior cerebral artery: a clinical series. *Neurol Neurochir Pol.* 2011 45:115-20.
2. Lee JY, Kim MK, Cho BM, et al. Surgical experience of the ruptured distal anterior cerebral artery aneurysms. *J Korean Neurosurg Soc.* 2007;42:281-5.
3. Yasargil M.G, Carter L.P. Saccular aneurysms of the distal cerebral artery. *J Neurosurg.* 1974;40:218-23.
4. Mann K.S, Yue C.P, Wong G. Aneurysms of the pericallosal-callosomarginal junction. *Surg Neurol.* 1984;21:261-6.
5. Orz Y. Surgical Strategies and outcomes for distal anterior cerebral arteries aneurysms. *Asian J Neurosurg.* 2011;6:13-7.
6. Kawashima M, Matsushima T, Sasaki T. Surgical strategy for distal anterior cerebral artery aneurysms: microsurgical anatomy. *J Neurosurg.* 2003;99:517-25.
7. Secer M, Ulutas M, Cinar K. Ruptured distal anterior cerebral artery aneurysms: a case series. *Turk J Cerebrovasc Dis.* 2016;22:56-60.
8. Ohno K, Monma S, Suzuki R, et al. Saccular aneurysms of the distal anterior cerebral artery. *Neurosurgery.* 1990;27:907-13.
9. Sindou M., Pelissou-Guyotat I., Mertens P., et al. Pericallosal aneurysms. *Surg Neurol.* 1988;30:434-40.
10. Hernesniemi J., Tapaninaho A., Vapalahti M., et al. Saccular aneurysms of the distal anterior cerebral artery and its branches. *Neurosurgery.* 1992;31:994-9.
11. Fukushima T., Miyazaki S., Takusagawa Y., et al. Unilateral interhemispheric keyhole approach for anterior cerebral artery aneurysms. *Acta Neurochir Suppl.* 1991;53:42-7.
12. Ng P.Y., Reilly P.L., Brophy B.P., et al. Distal anterior cerebral artery aneurysms: a clinical series. *Br J Neurosurg.* 1998;12:209-12.
13. Traynelis V.C., Dunker R.O. Interhemispheric approach with callosal resection for distal anterior cerebral artery aneurysms. *J Neurosurg.* 1992;77:481-83.